



PRESENTING CLINICAL SIGNS

History: Grade 4/6 systolic murmur.

DATE

4/25/22

ECHOCARDIOGRAPHIC FINDINGS

2D, M-mode, and Doppler study.

PERFORMED BY:

Kelly Vazquez

INTERPRETED BY

Keith Blass, DVM,
MS, DACVIM
(Cardiology)

There is mild to moderate left atrial dilation. The mitral valve leaflets are thickened and exhibit systolic prolapse. A moderate jet of eccentric mitral regurgitation is present. There is mild to moderate left ventricular dilation. Left ventricular systolic function is normal. The aorta and aortic valve are normal. Right atrial and right ventricular dimensions are normal. The tricuspid valve leaflets are mildly thickened, and a mild jet of tricuspid regurgitation is present. The pulmonary artery and pulmonic valve appear normal, though trace pulmonic insufficiency is present. No pericardial effusion or cardiac masses are seen.

LA - 38.1 mm
LVIDd - 38.0 mm
LVIDs - 22.4 mm
FS - 41%
RA - 21.5 mm
LVOT - 1.28 m/s
RVOT - 0.93 m/s
TR - 2.12 m/s

PATIENT

Indigo Goldstein

SPECIES

Canine

ASSESSMENT/RECOMMENDATIONS

Degenerative mitral and tricuspid valve disease

BREED

CKCS

SEX

MI

AGE

9 y

WEIGHT

27.5 lb

HOSPITAL NAME

Ringwood AH

REFERRING VET

Dr. Wilkes

This examination demonstrates regurgitation of blood across Indigo's mitral and tricuspid valves resulting from degenerative valve disease. Indigo's tricuspid valve disease is mild, and is well-compensated at this time. His mitral valve disease is more advanced, as Indigo has moderate mitral regurgitation present, with mild to moderate secondary dilation of both his left atrium and left ventricle, though his left ventricular systolic function is well-preserved. Indigo's mitral valve disease is still compensated, however, he could become at risk for the development of clinical signs, such as coughing, exercise intolerance, syncope, and labored breathing, if his disease progresses much further.

I recommend starting Indigo on pimobendan (5 mg am, 2.5 mg pm), as this medication should help to slow the progression of his valvular diseases.

A recheck echocardiogram is recommended in 6-9 months. Thoracic radiographs are recommended if Indigo experiences respiratory clinical signs.



DATE

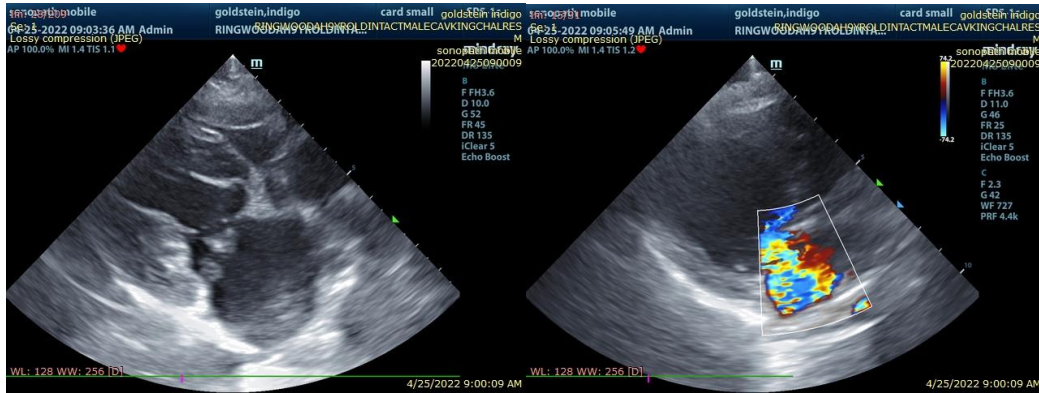
4/25/22

PERFORMED BY:

Kelly Vazquez

INTERPRETED BY

Keith Blass, DVM,
MS, DACVIM
(Cardiology)



The information and recommendations provided are based on the images presented by the referring veterinarian. No evaluation can be communicated regarding pathology that was not visible in the image/video clips provided.

Thank you for this referral. If the clinical or image interpretation does not parallel your findings or if I can be of any further assistance please contact me.

PATIENT

Indigo Goldstein

Keith Blass, DVM, MS, DACVIM (Cardiology)
KeithBlass@gmail.com
631-804-5754

SPECIES

Canine

BREED

CKCS

SEX

MI

AGE

9 y

WEIGHT

27.5 lb

HOSPITAL NAME

Ringwood AH

REFERRING VET

Dr. Wilkes